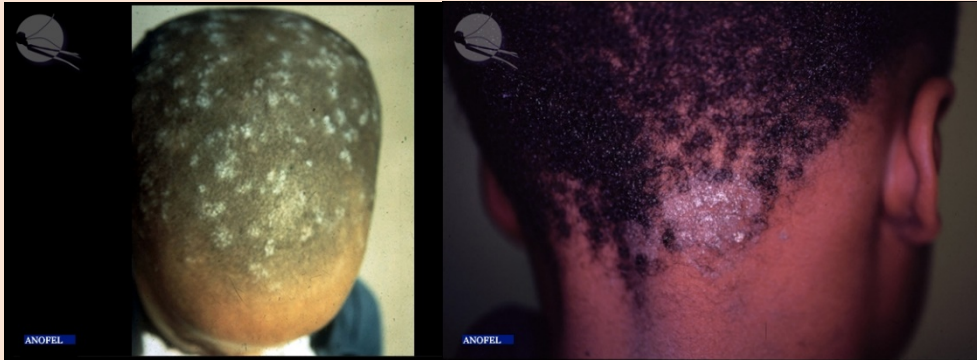
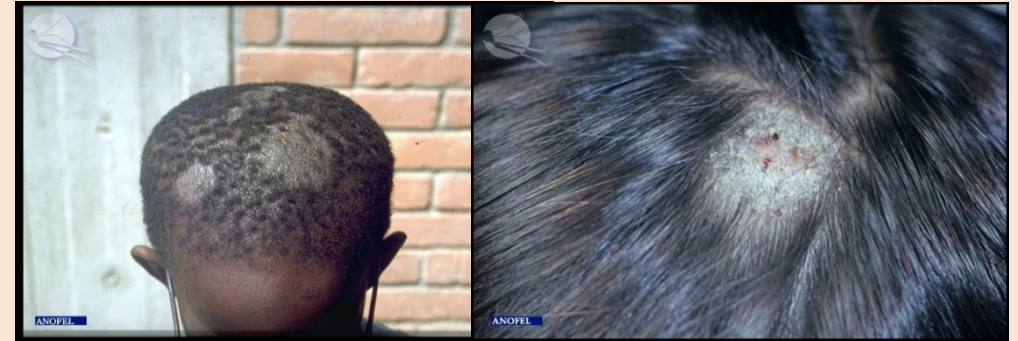
Clinical suspicion of tinea capitis in children

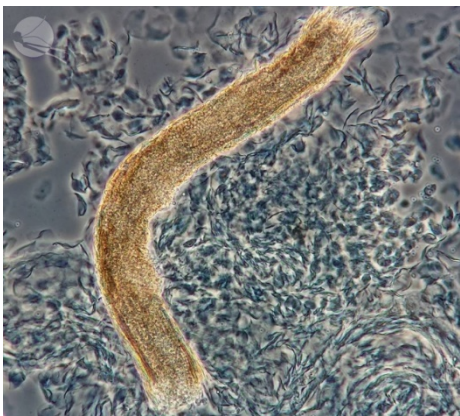Trichophytic tinea capitis: numerous small alopecic plaques, hair broken at the scalp (70% of cases); or even simple scaly condition



Microsporum tinea capitis: large alopecic plaques few in number, hair broken a few mm from the scalp (30% of cases)

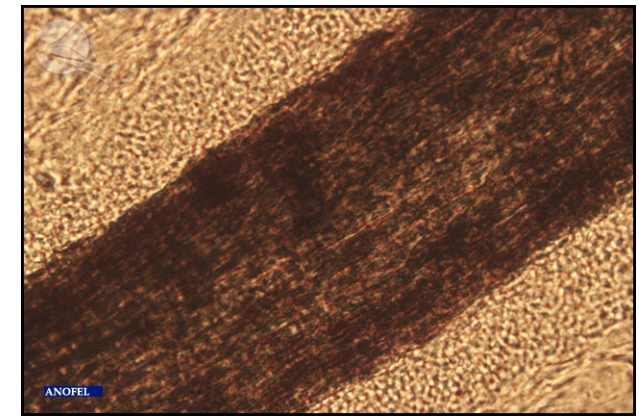
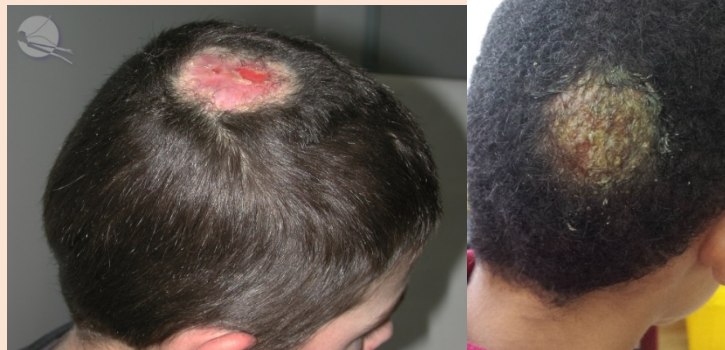

In all cases: mycological specimen recommended



Endothrix hair invasion
(trichophytic)

Inflammatory tinea
(most often of animal origin)



Endo-ectothrix hair invasion
(microsporic)