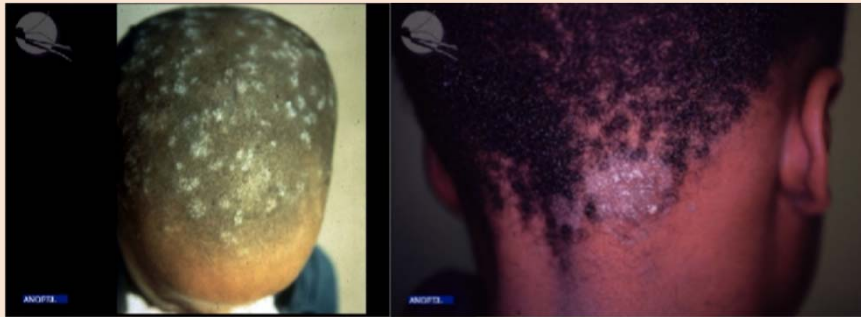
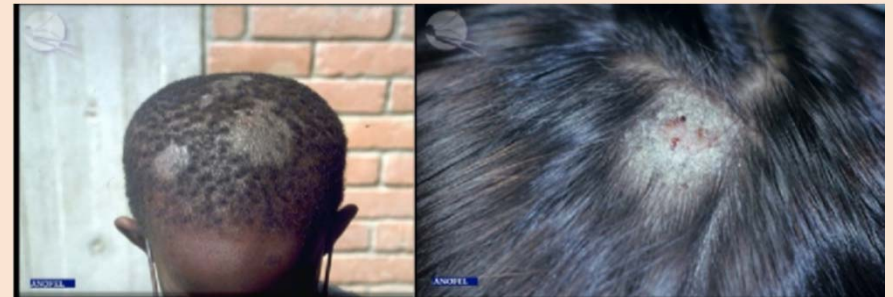
Clinical suspicion of tinea capitis in children

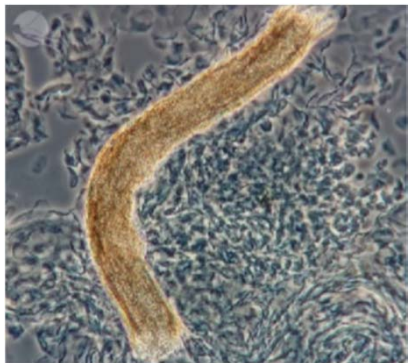Trichophytic tinea capitis: numerous small patches of alopecia, broken hair above the scalp surface (70% of cases); in some cases, only diffuse scale



Microsporic tinea capitis: sparse, large patches of alopecia, broken hair/ a few mm from the scalp (30% of cases)

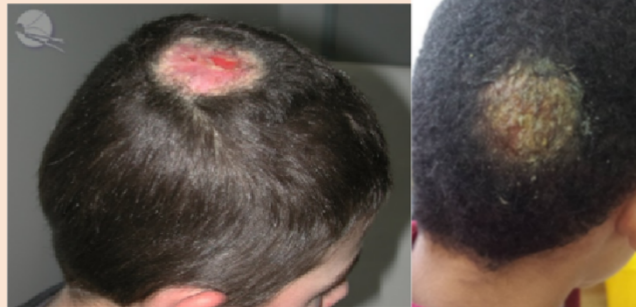


In all cases: mycological specimen collection recommended



Endothrix invasion of the hair (trichophytic infection)

Inflammatory tinea capitis
(mainly caused by zoophilic fungi)



Endo-ectothrix invasion of the hair (microsporic infection)